

# Shoulder Tendon Transfers

## Indications, Techniques and Outcomes

Charlie Talbot  
Upper Limb Fellow  
August 2011



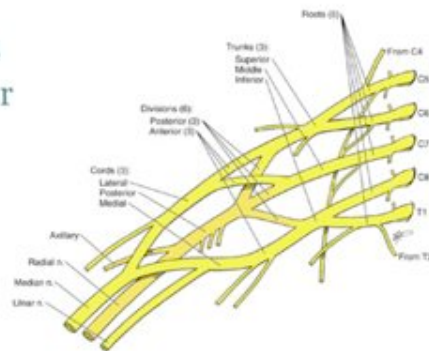
## Introduction

- Irreparable Rotator Cuff Tears
- Combined transfer with Arthroplasty
- Nerve injury

Not BPI as whole topic in itself and is usually managed by plastic surgeons

## Brachial Plexus Injury

- Good understanding
  - Nerve repair techniques
  - Muscle / tendon transfer
  - Outcomes
  - Anatomy
  - Biomechanics



Enhancement of upper-extremity function, specifically shoulder function, after brachial plexus

injury requires a good understanding of nerve repair and transfer, with their expected outcome,

as well as shoulder anatomy and biomechanics enabling the treating surgeon to use available

functioning muscles around the shoulder for transfer, to improve shoulder function. Surgical

treatment should address painful shoulder subluxation in addition to improvement of function.

L'Episcopo transfers of latissimus dorsi and teres major by an osteoperiosteal flap from anteromedial to posterolateral aspect of the humerus in addition to releasing subscapularis, pectoralis major and joint capsule.

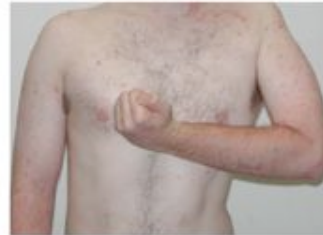The literature focuses on improving shoulder abduction, but improving shoulder external rotation

should take priority because this function, even if isolated, will allow patients to position their

hand in front of their body. With a functional elbow and hand, patients will be able to

## Brachial Plexus Injury

- Literature focus
  - Abduction
  - Reduction of GH subluxation
  - Elbow flexion
  - **BUT ? ER shoulder as /more important**



The literature focuses on improving shoulder abduction, but improving shoulder external rotation should take priority because this function, even if isolated, will allow patients to position their hand in front of their body. With a functional elbow and hand, patients will be able to do most activities of daily living.

## Relevance?

- Gerber 1988
  - Described LDT for postero-superior cuff tear
  - Based on work for BPI

- Latissimus Dorsi Transfer for the Treatment of Massive Tears of the Rotator Cuff A Preliminary Report
- GERBER, CHRISTIAN M.D.; VINH, THO SON M.D., PH.D.; HERTEL, RALPH M.D.; HESS, CHRISTIAN W. M.D.

In 1988, Gerber et al s reported encouraging results with the use of the latissimus dorsi muscle flap as a transfer for these irreparable rotator cuff defects associated with insufficiency of the rotator cuff. They stated that the muscle not only acted as a tenodesis to the humeral head, but presumably, because of the intact neurovascular pedicle, hypothesized that the muscle could potentially be an active humeral head depressor and external rotator, especially with the arm in the abducted position. They suggested an intact subscapularis muscle was necessary.

## Rotator Cuff Deficiency

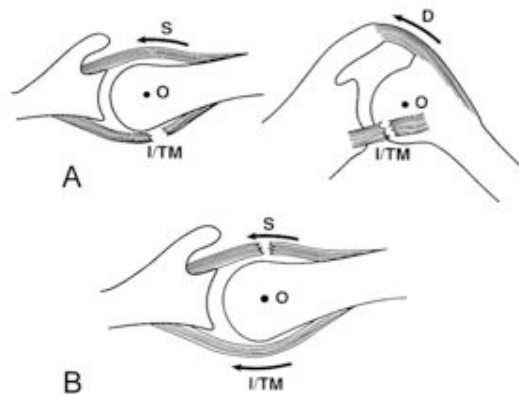
- **Latissimus dorsi**
- Teres major
- Pec Major
- Combinations

## Rotator cuff biomechanics

- Assists mid-range GHJ stability

- “Force Couple”

- Coronal
- Transverse
- Burkhart



The glenohumeral joint is highly mobile, with little bony or ligamentous stability provided in mid-range. Mid-range stability is provided by the rotator cuff in a function termed ‘concavity compression’ (Lippitt et al. 1993; Lippitt & Matsen 1993), where the stabilizing force of the rotator cuff contraction compresses the convex humeral head into the concavity of the glenoid. The rotator cuff can also be considered the ‘fine tuner’ of the glenohumeral joint (Wilk 1994). The force couples associated with elevation of the arm have two components – a coronal plane force couple between deltoid and supraspinatus superiorly and the lower elements of the rotator cuff inferiorly, and a transverse force

couple between subscapularis anteriorly and infraspinatus /teres minor posteriorly (Saha 1971; Poppen & Walker 1978; Kapandji 1982; Soderberg 1986; Schenkman & Rugo de Cartaya 1987, 1994; Norkin and Levangie 1988; Wilk 1994; Burkhart 1994, 1996). The transverse force couple is responsible for maintaining the humeral head centred in the glenoid during dynamic activity. A relative balance must be maintained between the activity in subscapularis and that in infraspinatus and/or teres minor for the centring function to be achieved. In relation to elevation, failure within the transverse force couple will lead to failure of the coronal plane force couple, as the compression component of the function will be missing, allowing the pull of deltoid to translate the humeral head superiorly under the acromion (Saha 1971; Poppen & Walker 1978; Kapandji 1982; Soderberg 1986; Schenkman & Rugo de Cartaya 1987, 1994; Norkin & Levangie 1988; Wilk 1994; Burkhart 1994, 1996)

Burkhart et al 4,6 suggested that if the rotator cuff is balanced with an intact anterior posterior force couple, closure of that rotator cuff defect, which perhaps is not repairable, may not be necessary. In these cases, they suggested that the balanced force couples of the rotator cuff will allow the patient continued function and debridement and decompression may be all that is necessary to alleviate the pain.

## Indication for tendon transfer

- MRCT / Weakness
- Functional strength loss +/- pain
- Intact antagonist muscle
  - Maintain the “force couple” in MRCT
- Intact deltoid
- Good bone – fixation
- Compliant patient (young active)



## Pre-requisites of Transfer

- One motor, one function
- Synergism
- Straight line pull
- Excursion
- MRC Power 5
- Mobile joint
  
- Expendable / Gain better than loss

## Irreparable cuff tears

- **CLEER**
  - Supra, infraspinatus +/- teres minor
- **ILER**
  - Deltoid compensation
- **IR weakness**
  - Subscap deficiency

Postero superior

Anterior

Combination

## Clinically

- Pain
- Weakness
- Periscapular atrophy
- Function loss
  - Including ADLs
- Unstable kinematics
  - Postero- or antero- superior MRCTs

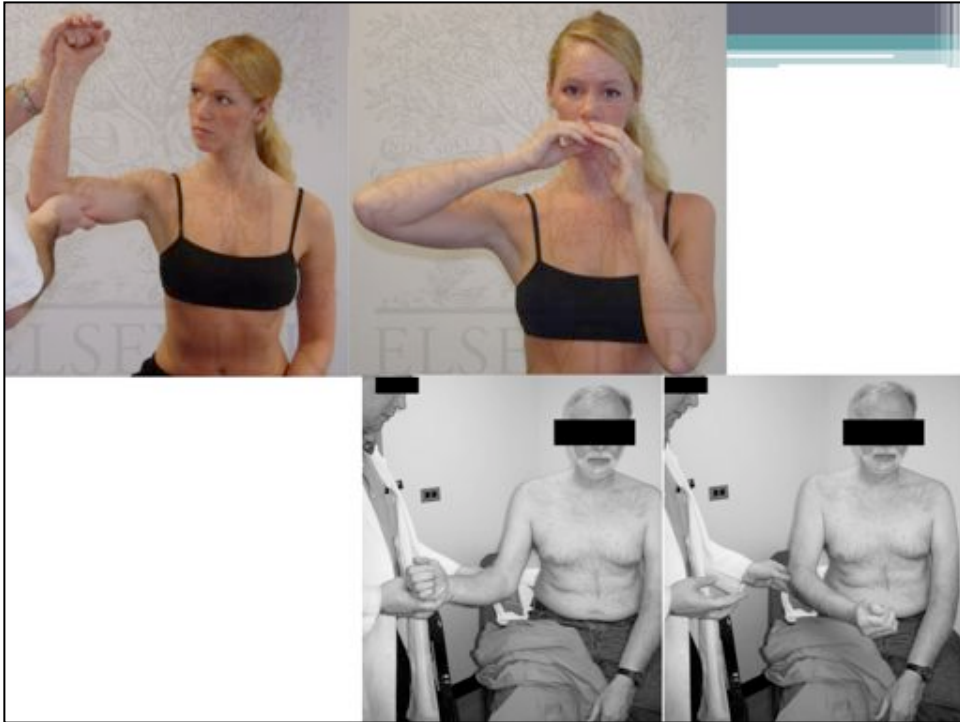
The size of the rotator cuff tear has a significant effect on the clinical result after a surgical repair. Larger tears are associated with persistent defects, residual weakness, and

inferior outcomes.<sup>38</sup> Massive tears are classified as anterosuperior or posterosuperior, each with unique incidence, clinical presentation, examination findings, and prognosis. These tears can cause an uncoupling of forces across the glenohumeral joint and result in unstable shoulder kinematics. Physical examinations in these patients are likely to reveal pain, periscapular atrophy, and profound weakness

Using ultrasound and standard radiographic evaluation, Keener et al. demonstrated that a significantly greater amount of proximal humeral migration occurred in tears

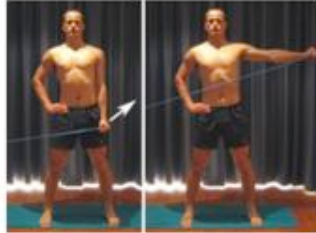
involving the infraspinatus than isolated tears of the supraspinatus, and tear size was the only independent predictor of proximal humeral migration

Keener JD, Wei AS, Kim HM, et al. 2009. Proximal humeral migration in shoulders with symptomatic and asymptomatic rotator cuff tears. *J Bone Joint Surg Am* 91:1405–1413.



## Management

- Deltoid rehab
- Debridement / ASAD (- CAL release)
- Partial cuff repair
  - Restore transverse force couple
  - Allows deltoid compensation



Burkhart (1994) / Duralde and Bair (JSES 2005)

Hsu - Rat model 2 tendon vs. 1 - similar results

Duralde XA, Bair B. 2005. Massive rotator cuff tears: the result of partial rotator cuff repair. *J Shoulder Elbow Surg* 14:121-127.

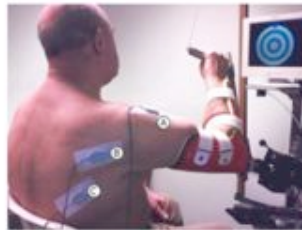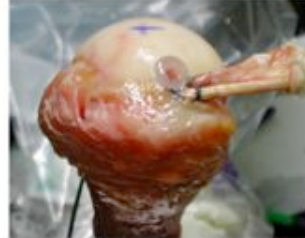Massive rotator cuff tears often defy traditional repair techniques and have led to a variety of treatment recommendations. We reviewed retrospectively the results of partial repair of massive rotator cuff tears in 24 patients. Overall results were excellent in 11 patients (46%), good in 5 (21%), fair in 7 (29%), and poor in 1 (4%). Ninety-two percent of patients were satisfied with the result of surgery. Satisfactory pain relief was achieved in 83% ( $P < .001$ ). Active elevation improved from 114 degrees to 154 degrees, and no patient lost strength after surgery. The ability to raise the arm to at least 135 degrees improved from 13 patients preoperatively to 21 patients postoperatively. This series serves as a basis of comparison to debridement, tendon transfers, and tendon augmentation procedures for the treatment of massive irreparable rotator cuff tears.

Burkhart SS, Nottage WM, Ogilvie-Harris DJ, et al. 1994. Partial repair of irreparable rotator cuff tears. *Arthroscopy* 10:363-370

This study analyzes the results of a previously unreported technique of reconstruction for the massive irreparable rotator cuff tear. The technique involves repair of the margins of the tear to restore the force couples and "suspension bridge" system of force transmission in the shoulder. Complete coverage of the defect was not considered to be essential as long as the normal mechanics of the shoulder were restored and the rotator cuff tear was converted to a "functional cuff tear." This procedure was performed on 14 patients. Improvement in function was dramatic. Active elevation (elevation denotes the plane of motion midway between the planes of shoulder abduction and shoulder flexion; elevation is reported because it is the most functional plane in which to raise the arm) improved by 90.8 degrees: from a preoperative average of 59.6 degrees to a postoperative average of 150.4 degrees. Strength improved an average of 2.3 grades on a 0-to-5-point scale. The average score on the UCLA Shoulder Rating Scale improved from a preoperative value of 9.8 to a postoperative value of 27.6. All but one patient was very satisfied with his or her result. The authors are of the opinion that this technique is preferable to other reconstructive techniques, such as tendon transposition, that emphasize coverage of the defect at the expense of

## Basic Science

$$J = \sum_{i=1}^n \left( \frac{F_i}{PCSA_i} \right)^2$$

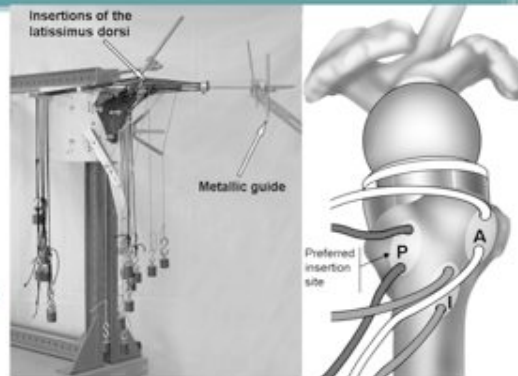


## Neuroanatomy

- Pearle et al (JBJS 2007)
  - Humeral insertion LD  $\Rightarrow$  TDN = 13.1cm
  - Humeral insertion TMj  $\Rightarrow$  Lower subcap n. = 7.4cm
  - Puts nerve at risk in combined transfer

## Biomechanics

- Gerber JSES 2008
- 3 different insertion sites
- Ant / post / inf GT



- **Posterior most biomechanically advantageous to ER**

Latissimus dorsi transfer to restore external rotation with reverse shoulder arthroplasty: A biomechanical study  
Philippe Favre, MSc, Michael D. Loeb, MD, Naeder Helmy, MD, and Christian Gerber, MD, Zurich, Switzerland  
J Shoulder Elbow Surg 2008;17:650-658.

Latissimus dorsi transfer to restore external rotation with reverse shoulder arthroplasty: A biomechanical study

Philippe Favre, MSc, Michael D. Loeb, MD, Naeder Helmy, MD, and Christian Gerber, MD, Zurich, Switzerland

J Shoulder Elbow Surg 2008;17:650-658.



## Biomechanics: Role of subscapularis in LDT

- Clinically poorer results
- 10 FF cadaveric humerii, LDT / created MRCT

	Subscap loaded	Subscap not loaded
ER	13mm post	19mm anterior
AbER	10 mm post	32 mm anterior

- **Intact subscap improves stability**

Werner CM, Zingg PO, Lie D, et al.

The biomechanical role of the subscapularis in latissimus dorsi transfer for the treatment of irreparable rotator cuff tears. *J Shoulder Elbow Surg.* 2006;15:736--742.

Werner CM, Zingg PO, Lie D, et al. The biomechanical role of the subscapularis in latissimus dorsi transfer for the treatment of irreparable rotator cuff tears. *J Shoulder Elbow Surg.* 2006; 15:736--742.

The authors provided the first biomechanical explanation for why a latissimus dorsi transfer provides better results with an intact subscapularis than a torn subscapularis. They developed a biomechanical model using cadaver humeri, performed latissimus tendon transfers with and without loading the subscapularis, and showed that the subscapularis improved stability of the glenohumeral joint with the tendon transfers.

Biomechanical analysis of tendon transfers for massive rotator cuff tears

D.J. Magermans <sup>a,\*</sup>, E.K.J. Chadwick <sup>a</sup>, H.E.J. Veeger <sup>a</sup>, F.C.T. van der Helm <sup>a</sup>,  
P.M. Rozing <sup>b</sup>

$$J = \sum_{i=1}^n \left( \frac{F_i}{PCSA_i} \right)^2$$

- Transfer **teres major**  $\Rightarrow$  **supraspinatus** insertion  
= **best functional outcome**

---

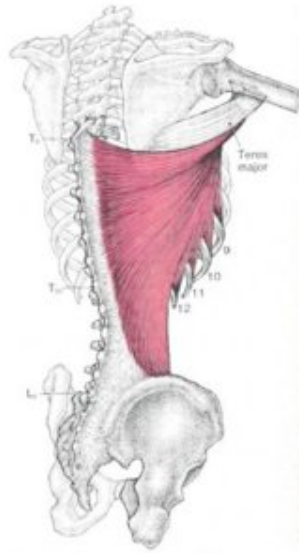
CLINICAL  
BIOMECHANICS

---

Muscle forces are distributed, based on the following cost function:

where  $n$  is the number of muscle elements,  $F_i$  is the force and  $PCSA_i$  the physiological cross-sectional area. In contrast to non-linear cost functions, which are physiologically more realistic, linear cost functions do not solve the load-sharing problem, they predict the sequential recruitment of muscles (Tsirakos et al., 1997).

## Techniques LDT

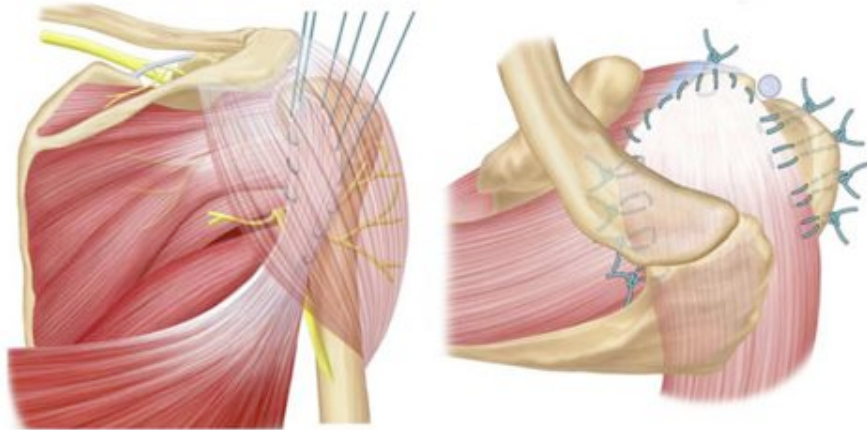


## Gerber original 2 incision

- Posterior incision – harvest
  - LD – detached from its humeral insertion
- Deltoid split
  - With proximal detachment
  - LD ⇒ GT, LT and subscapularis

Classical description

## Gerber Posterior / Lateral LDT



Transosseous fixation and to subscap

## Reversed shoulder Arthroplasty with modified L'Episcopo for combined loss of active elevation and external rotation

Pascal Boileau, MD\*, Adam P. Rumian, MD, FRCS, Matthias A. Zumstein, MD

- Single open incision
- Isolated MRCT or + RSA
- Modified L'Episcopo procedure
  
- Proximal shaft insertion
- Sutured to released pec m tendon

JOURNAL OF  
SHOULDER AND  
ELBOW  
SURGERY

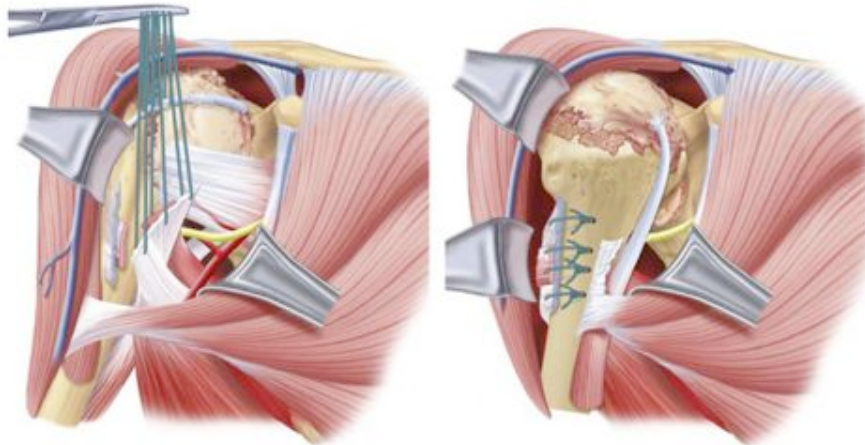
L'Episcopo transfers of latissimus dorsi and teres major by an osteoperiosteal flap from anteromedial to posterolateral aspect of the humerus in addition to releasing subscapularis, pectoralis major and joint capsule

Modified latissimus dorsi and teres major transfer through a single delto-pectoral approach for external rotation deficit of the shoulder: As an isolated procedure or with a reverse arthroplasty

Pascal Boileau, MD, Christopher Chuinard, MD, MPH, Yannick Roussanne, MD, Lionel Neyton, MD, and Christophe Trojani, MD, Nice, France

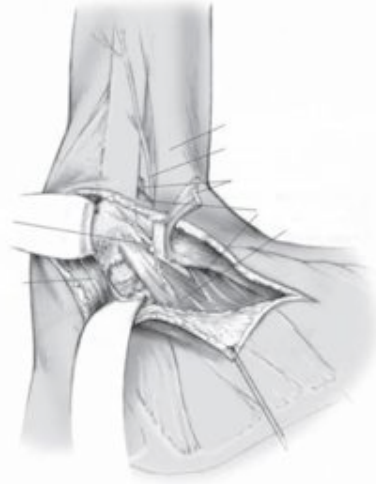
J Shoulder Elbow Surg 2007; 16:671-682

## Boileau Deltopec Single



Boileau et al. reported a novel technique for a latissimus and teres major transfer through a deltopectoral exposure (Figure 1A). The results were reported in 15 patients with an average follow-up of 38 months. The upper half of the pectoralis is tenotomized at the myotendinous junction with heavy stay sutures placed to allow for reattachment. The latissimus and teres major are sharply transected and rerouted around the posterior portion of the humerus to be reattached onto the pectoralis stump. Alternatively, transosseous repair at the greater tuberosity can be accomplished as during a reverse shoulder arthroplasty. The humerus is distalized, and the attachment to the tuberosity is facilitated

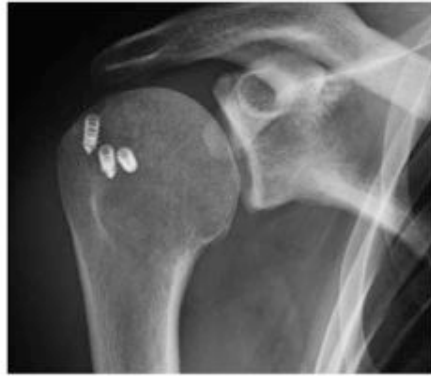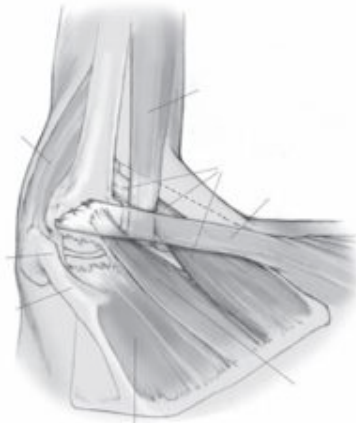
## Single Posterior



Harbermeyer JBJS 2006



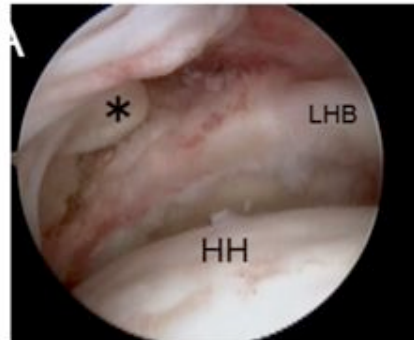## Single Posterior



Harbermeyer JBJS 2006

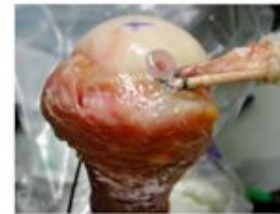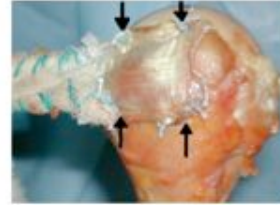## Arthroscopic Techniques

- Mini-open graft harvesting
- Arthroscopic transfer
  - upper subscap
  - supraspinatus
  - infraspinatus
- Grimberg (Techn SES 2010)
- Millet (Techn SES 2008)
- Gervasi (Arthroscopy 2007)



## Arthroscopic Fixation Techniques

- Transosseous sutures
- Suture anchors
- Biotenodesis screw



Tendon fixation in arthroscopic latissimus dorsi transfer for irreparable posterolateral cuff tears: An in vitro biomechanical comparison of interference screw and suture anchors  
Diop / Grimberg: Clinical Biomechanics 2011

Tubularise the tendon for interference screw fixation

All anchor fixed specimens failed by tendon tear at the tendon-anchors interfaces and none of the anchors pulled out

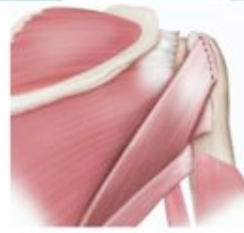Background: The fixation of the tendon to the bone remains a challenging problem in the latissimus dorsi tendon transfer for irreparable cuff tears and can lead to unsatisfactory results. A new arthroscopic method of tendon to bone fixation using an interference screw has been developed and the purpose of this study was to compare its biomechanical properties to the ones of a standard fixation technique with anchors. Methods: Six paired fresh frozen cadaveric human humeri were used. The freed latissimus dorsi tendon was randomly fixed to the humeral head with anchors or with interference screw after a tubularization procedure. Testing consisted to apply 200 cycles of tensile load on the latissimus dorsi tendon with maximal loads of 30 N and 60 N, followed by a load to failure test. The stiffness, displacements after cyclic loadings, ultimate load to failure, and site of failure were analysed. Findings: The stiffness was statistically higher for the tendons fixed with interference screws than for the ones fixed with anchors for both 30 N and 60 N loadings. Likewise, the relative bone/tendon displacements after cyclic loadings were lower with interference screws compared to anchors. Load to failure revealed no statistical difference between the two techniques. Interpretation: Compared to the standard anchor fixation, the interference screw fixation technique presents higher or similar biomechanical performance. These results should be completed by further biomechanical and clinical trials to confirm the interest of this new technique as an alternative in clinical use.

We believe that this technique is easier to perform arthroscopically than the anchor technique, as there is no need to manipulate thin tendon and different anchors and sutures under arthroscopic control.

## Results LDT

- RCT not appropriate / feasible
- Evidence cohorts / large case series

## Results LDT



- Weening and Willems (Int Orthop 2010)
  - 16 LDT
  - Poor results with Subscap Tear
  - Increased movement NOT strength
- Coustouros et al (JSES 2007)
  - Evaluated teres minor integrity & outcome
  - Fatty infiltration correlated with outcome
  - Assess pre-operatively

Costouros et al.<sup>18</sup> evaluated the potential influence of teres minor integrity on the outcome in 16 men and six women with an average follow-up of 34 months after latissimus dorsi tendon transfer using the technique of Gerber et al.<sup>7</sup> The patients were divided into two groups; group A included Goutalier stage 0, 1, and 2 fatty infiltration of the teres minor,<sup>19,20</sup> and group B included patients with more than stage 2 changes on preoperative scans. The presence of a partial tear of the teres minor had a smaller effect than the degree of fatty infiltration of the teres minor. The presence of fatty infiltration of the teres minor greater than stage 2 was associated with greater pain before and after surgery, worse functional scores, less external rotation after surgery, and less forward elevation after surgery than other patients. The authors recommended assessing the degree of fatty infiltration of the teres minor

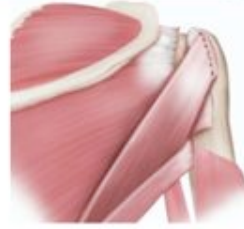before proceeding with a latissimus transfer because it was predictive of the end result. The average postoperative external rotation in group A was 361 and in group B was 161.

## Results LDT



- Zafra et al (Int Orthop 2009)
  - 18 LDT, 2 incision tech
  - Improved Constant 21 points
  - **2 infections (>10%)**
  - Recommend young active
  - Prolonged rehab

## Results LDT



- Irlenbusch et al (JSES 2008)
  - 52 LTD
  - Best results
    - Primary procedure
    - Isolated postero-sup cuff
    - Intact subscap
    - No instability
    - No deltoid pathology
  - Continued improved outcome scores

## Results LDT



- **Birmingham and Nevaizer (JSES 2008)**
  - Salvage failed RC repair (n=19)
  - Loss elevation
  - 94% Satisfied
- **Gerber (JBJS Am 2006)**
  - 2 incision (n=69)
  - Worse with poor subscap function
  - Improved pain / flexion / abduction / ER / scores



## Results LDT



- Miniaci and MacLeod (JBJS 1999)
  - n=17
  - 2-5 yr f/u
  - Improved pain / satisfaction and function
  - No infection

## Results LDT - Arthroscopy



- Gervasi et al (Arthroscopy 2007)
  - Technique, no results
- Millett, Yen, Huang (Techn SES 2008)
  - Technique, no results

Millett, P.J., Yen, Y.M., Huang, M.J., 2008. Arthroscopically assisted latissimus dorsi transfer for irreparable rotator cuff tears. *Techn. Shoulder Elbow Surg.* 9, 76–79.

## Results LDT - Arthroscopy



- **Grimberg (Techn SES 2010)**
  - Interference screw
  - N=17
  - Good to excellent results
  - Comparable to other fixations


## LDT & Teres Major Transfer

- Boileau
  - 11 pts with RSA
  - Mean increased elevation 70° / 36°
- Gerhardt
  - 20 pts modified L'Episcopo
  - Meta-diaphysis attachment
  - Good results
- No proven benefits adding TMjT

It has not been proven that adding the teres major tendon to the latissimus dorsi tendon gives better results although a few authors advocate this technique (Boileau et al., 2007; Herzberg et al., 1999; Schoierer et al., 2001).

## Clinical outcome: TMj transfer

- Steenbrink et al.
  - Clinical Biomechanics 2010
  - Isolated TMjT  $\Rightarrow$  supraspinatus footprint (MRCT)



Background: In massive rotator cuff tears a teres major (TMj) tendon transfer to the insertion of the supraspinatus (SSp) reverses its adduction moment arm into abduction which is supposed to be an adequate salvage procedure. Analysis of muscle function to find biomechanical ground of such success is scarce.

Methods: We compared pre- and postoperative clinical outcome of TMj transfer, i.e. Range of Motion, pain, Constant Shoulder scores and arm force. TMj activation was evaluated in 14 patients suffering massive cuff tears using activation ratios to describe the desired 'in-phase' and undesired 'out-of-phase' contribution to the external arm moment. Additionally, we analyzed activation of the latissimus dorsi (LD) and the medial part of the deltoids (DE). The activation ratios were compared to controls and TMj activation ratios were related to clinical outcome.

Findings: TMj tendon transfer improved arm function. Pre-operatively, we observed 'out-of-phase' abduction activation of TMj and LD. After transfer patients activated TMj according to its new anatomical position. 'Out-of-phase' LD abduction activation persisted. The clinical improvements coincided with changes in activation ratio of TMj.

Interpretation: 'Out-of-phase' TMj adductor activation is associated with compromised arm function in patients with irreparable cuff tears. After transfer, TMj is activated in correspondence with its new anatomical function, which was supportive for the improved arm function.

## Clinical outcome: TMj transfer

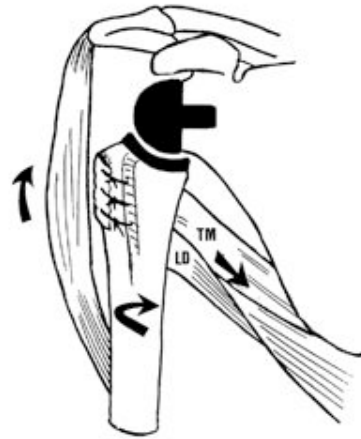
- Pre-op “out-of-phase” activity TMj
- Post-op “in-phase”
- Clinical outcome comparable to LDT
- Highlights “force couple” balancing
- Harvest concerns – use LDT

In this evaluation of TMj transfer in patients with massive rotator cuff lesions we found functional and clinical improvements and provide evidence that the TMj is functionally activated after transfer surgery.

This study also provides evidence for the biomechanical relation between TMj function before and after surgery with the observed functional and clinical improvements. The preoperative deteriorated arm function was associated with pathological ‘out-of-phase’ adductor muscle activation of both TMj and LD. This is assumed to be an attempt to accommodate for better glenohumeral stability in the cranially migrating humeral head. After surgery patients were able to activate TMj in correspondence with its new anatomical function, delivering a stabilizing force component at the humeral head. This study illustrates the importance of biomechanical force and moment balance in rotator cuff pathology and tendon transfer surgery.

## LDT & reverse geometry arthroplasty

- Cuff tear arthropathy
- Reverse geometry arthroplasty
- No active ER recovery
  - ? Combining LD TT



Reverse shoulder arthroplasty (RSA) is rapidly gaining acceptance as an effective treatment; shoulder function, however, requires not only active elevation but also control of active external rotation.

There is sufficient evidence that recovery of active external rotation is not achieved with reverse prostheses and may remain the most significant functional

problem for the patient with shoulder pseudoparesis

Boileau P, Watkinson DJ, Hatzidakis AM, Balg F. Grammont reverse prosthesis: design, rationale, and biomechanics. *J Shoulder Elbow Surg* 2005;14:147S-61.

Werner CM, Steinmann PA, Gilbert M, Gerber C. Treatment of painful pseudoparesis due to irreparable rotator cuff dysfunction with the Delta III reverse-ball-and-socket total shoulder prosthesis. *J Bone Joint Surg Am* 2005;87:1476-86.

## Clinical results of LTD & RSA

- Gerber et al (JBJS 2007)
  - N=18
  - Tx to postero-inferior GT
  - Mean gain: ER 7°, flexion 45°
  - Subscap deficiency not contraindication
- Boileau et al (JSES 2010)
  - N=17
  - LDT + TMj
  - Mean gain: ER 34° flexion 75°
  - Improved scores, ADLs



## Combined Pec and LDT

- MRCT involving postero-superior and anteriorly
- 11 patients
- mean increase elevation 42° - 86°
- mean increase ER
- 5 good / 2 average / 4 no better

**Combined pectoralis major and latissimus dorsi tendon transfer for massive rotator cuff deficiency.**

Aldridge JM 3rd, Atkinson TS, Mallon WJ.  
[J Shoulder Elbow Surg. 2004 Nov-Dec;13\(6\):621-9.](#)

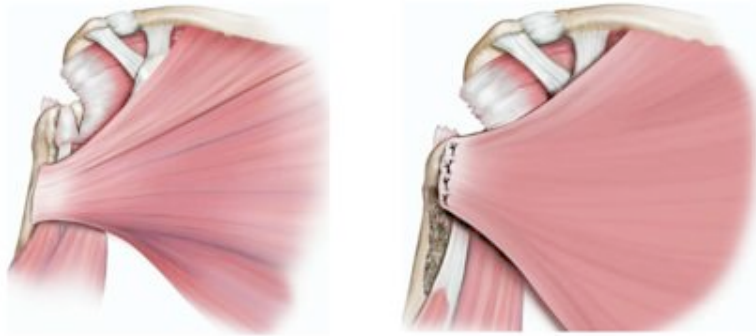
Failure seen by Gerber in patients with subscap tears following LDT therefore combined PMT and LDT

This report is a retrospective review of 11 consecutive patients treated with a combined transfer of the latissimus dorsi and pectoralis major tendons for massive rotator cuff deficiency. Each patient's chief complaint was diminished shoulder function and motion with little or no accompanying pain. The primary operative objective was to increase active shoulder motion. All 11 patients were followed up for at least 2 years (range, 24 to 42 months). The mean active elevation improved from 42° preoperatively to 86° postoperatively. The mean active external rotation improved from 0° to 13°. On the basis of the Medical Research Council scale, the mean abduction strength improved from 2.3 to 3.1 and the mean external rotation strength improved from 2.1 to 2.7. Overall, 4 patients made no improvement, 2 improved slightly, and 5 improved significantly. We conclude that a combined transfer of the latissimus dorsi and pectoralis major is a reasonable and safe procedure that may restore active elevation and external rotation in some patients' shoulders with a massive rotator cuff deficiency that have not responded favorably to traditional nonoperative and operative techniques. However, it is difficult to conclude, based on our experience, for which patients this surgery can be predictably successful. (J Shoulder Elbow Surg 2004;13:621-629.)

## Summary - LDT

- Poorer outcome
  - Revision surgery
  - Subscap deficient
  - Teres minor atrophy / deficiency
  - Deltoid deficiency
  - Instability
- Indicated to improve
  - Pain
  - Movement
  - Function
  - RSA?
- No real benefit TMj

## Pectoralis major transfer



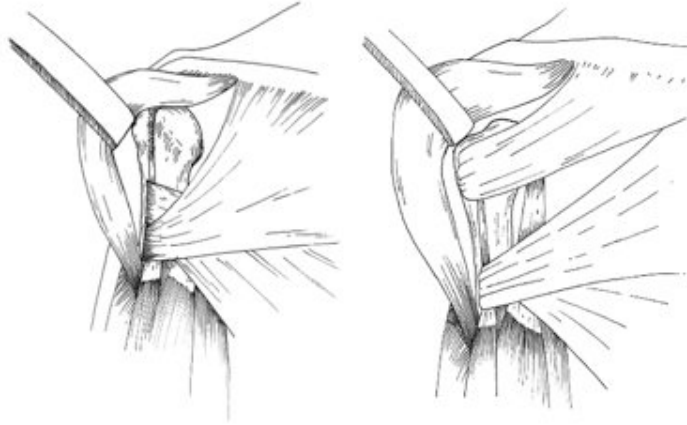
## Pectoralis major transfer indications

- Subscap deficiency
  - Irreparable chronic tears
  - Salvage for re-tears
  
  - Pain, loss function / strength
  - Fatty degeneration Subscap (Goutalier  $\geq 2$ )
  
- LTN palsy: serratus anterior
  - Scapula winging

Subscapularis is the most important muscle for stability and function of the glenohumeral joint.<sup>1,14,28-31</sup> It has an amplitude of 7.3 cm, making it the strongest of the rotator cuff muscles,<sup>1,32</sup> and it uses this strength in combination with great leverage to impart a strong rotational force to the shoulder. 1 Tearing, degeneration, and atrophy beyond the equator

of the subscapularis tendon results in loss of this mechanical advantage, which causes weakness and loss of containment of the humeral head against the glenoid.<sup>1,28,29,31,33</sup> Assessment of tissue quality with MRI before attempted repair of subscapularis is important, as excessive retraction or atrophy beyond Goutallier stage 2 makes successful repair unlikely

## Split tendon transfer

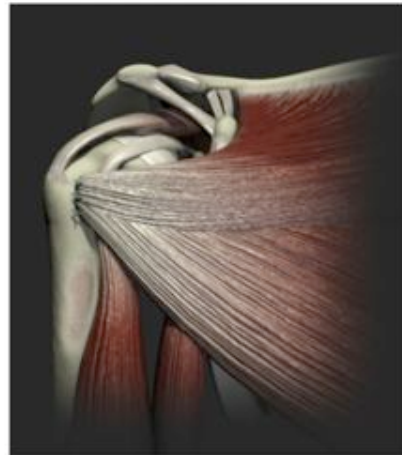


Wirth and Rockwood JBS 1997

Satisfactory outcomes 10/13 patients

## Entire Pec over Coracobrachialis

- Jost et al JBJS 2003
  - 30 patients
  - Goutallier  $\frac{3}{4}$
  - Retraction to glenoid
- Good / excellent 23
- Subjective Shoulder Value  
23% to 55%
- Constant score from 47 to 70

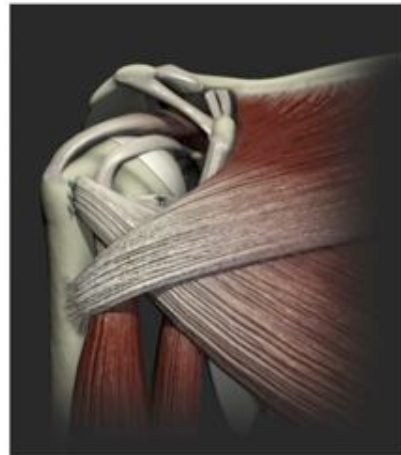


guideline for safe release, as the lateral and medial pectoral nerves were never found to enter the muscle lateral to this landmark.

Klepps SJ, Goldfarb C, Flatow E, et al: Anatomic evaluation of the subcoracoid pectoralis major transfer in human cadavers. J Shoulder Elbow Surg 10:453-459, 2001

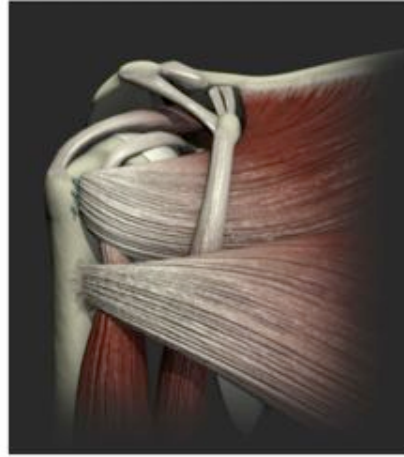
## Sternal head over CB under clavicular head

- Warner et al JBJS 2000
- N=10
- ? Better line pull pec
- 2 good improvement
- All reported less pain and greater stability



## Portion under CB

- Resch et al JBJS 2000
- Flexion 93  $\Rightarrow$  129
- Abduction 85  $\Rightarrow$  113
- Constant 26.9  $\Rightarrow$  67.1
- Decrease pain / ER



Musculocutaneous  
nerve

Staighter line of pull vs. musculocutaneous n injury

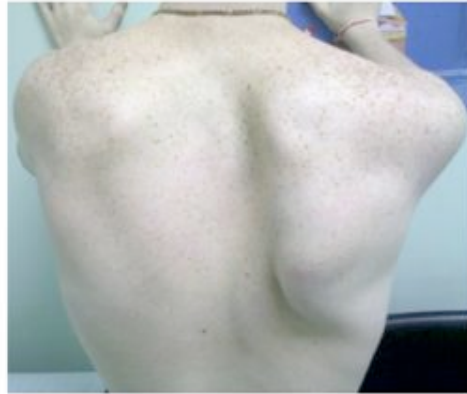

## Results PMT

- **Primary subscap repair better**
  - BUT good satisfaction as poor pre-op function
- **Complications**
  - Nerve injury
    - Musculocutaneous
    - axillary nerve
    - brachialplexus
  - Failure fixation
  - Recurrent anterior dislocation

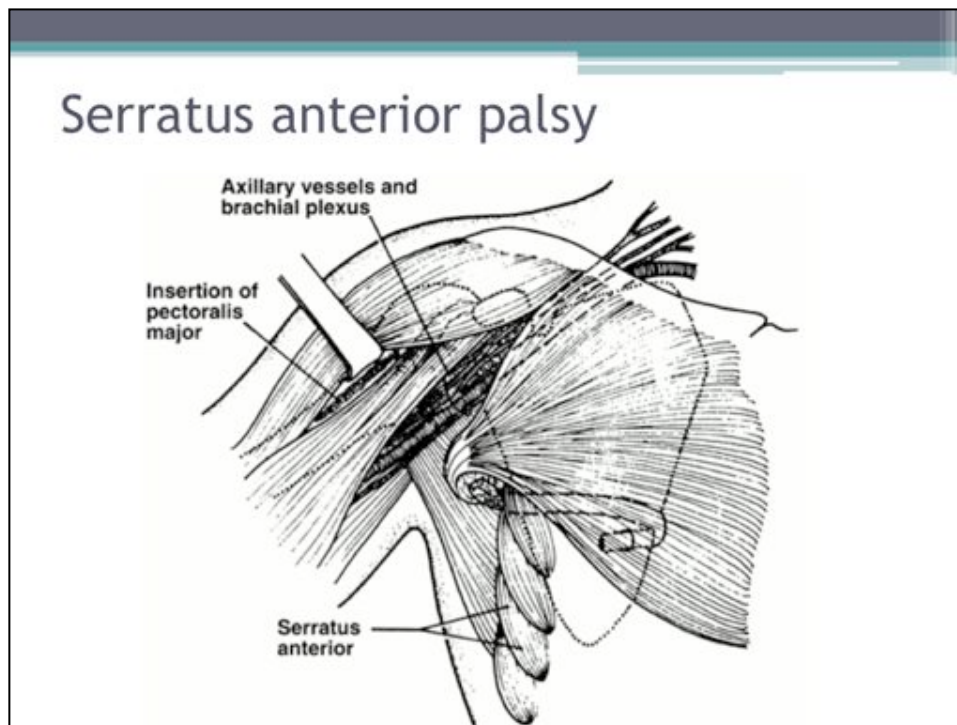
## Serratus anterior palsy

- Often spont recovery
- LTN C5,6,7
- Medial Winging



in most cases, serratus paralysis will resolve over 6 months

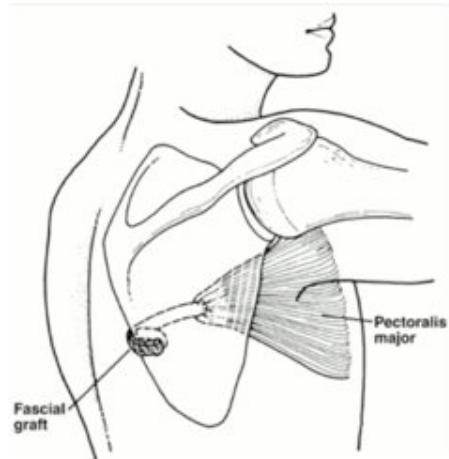
**split pectoralis major transfer:**



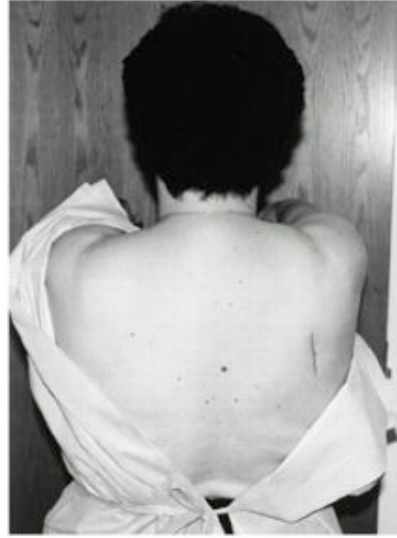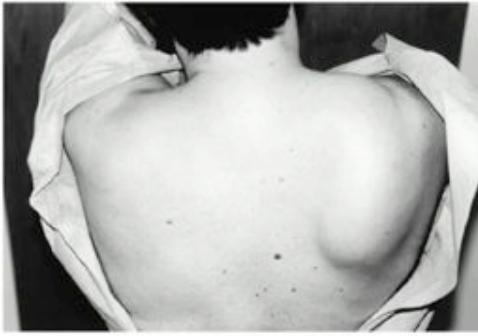Paralysis of the serratus anterior muscle can be functionally disabling. As a result of the scapular winging associated with such paralysis, the scapula does not remain apposed to the thorax when the upper extremity is elevated forward at the shoulder. This produces functional disability associated with pain and loss of a stable base for movement of the upper extremity. Methods: We reviewed the results of transfer of the pectoralis major tendon with the addition of a fascial graft in sixteen patients who had paralysis of the serratus anterior. The average age of the patients at the time of the operation was thirty-three years (range, twenty to fifty-five years). Electrodiagnostic studies confirmed the presence of an isolated injury of the long thoracic nerve. The index operation was performed sixteen months to eleven years after the onset of pain and weakness. The etiology of the paralysis was

## Serratus anterior palsy

- N=16
- EMG isolated LTN
- 16/12 – 11 years
- Av age 33
  
- Good 8
- Average 5
- Fair 1
- 2 traumatic failures
- Constant 36 ⇒ 92

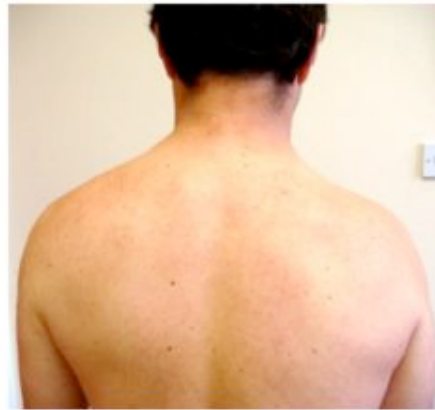

## Serratus anterior palsy



## Trapezius Palsy

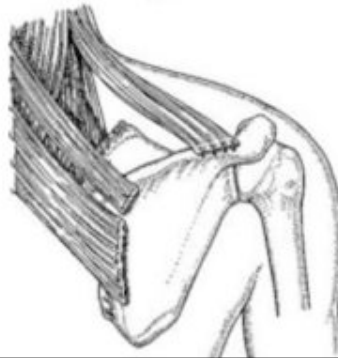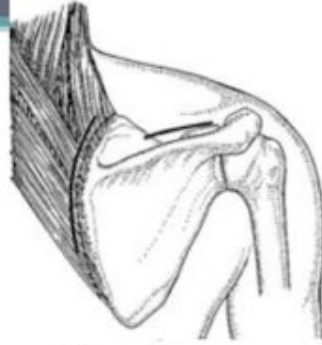- Post triangle node biopsy
- Penetrating Trauma
- Lat scapula winging / weak shoulder elevation



Injury to Spinal accessory nerve (Blunt injury neuropraxia will resolve within 12 months, lacerations will not heal and transfer indicated)

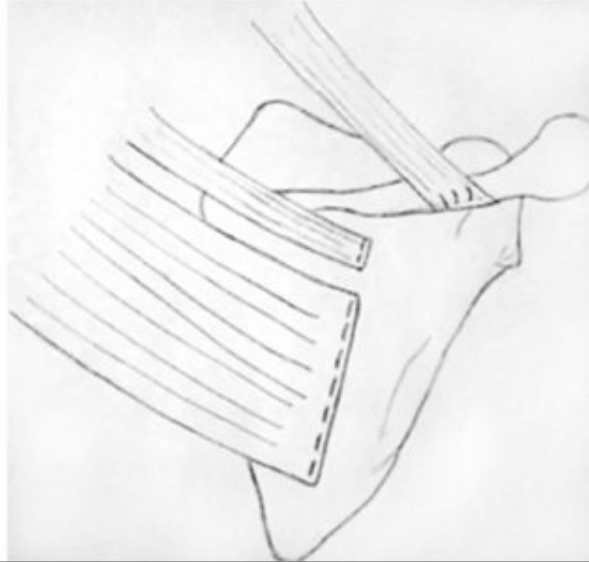## Eden-Lange

- LS → lateral spine
  - Sup traps
- Rh minor → s. fossa
  - Middle
- Rh major → i. fossa
  - Inf



Eden 1924 & Lange 1959

## Eden Lange Procedure







## Future

- Free muscle transfers
- Bioengineering techniques ?

## LDT indications

- **Postero-superior irreparable cuff tears**
  - Combined loss elevation and external elevation
  - CLEER
  - Pain
- **With reverse geometry shoulder arthroplasty**
- **Post tumour resection**
  - With excision of the cuff
- **Isolated nerve injury**

tumor resection with sacrifice of the rotator cuff represents a similar clinical scenario with an iatrogenic combined loss of elevation and external rotation, and few reconstructive options